In Person + Live Streaming
TTS 2024 ISTANBUL TURKEY
September 22-25
+ Virtual October 21-23

Using Double J Stent in Liver Transplant to Prevent Bile Leak

Mehmet Haberal[1], Emre Karakaya[1], Sedat Yildirim[1], Adem Şafak[1], Fatih Boyvat[2], Özgür Özen[2], Sedat Boyacioğlu[3]

[1]Baskent University, Department of General Surgery, Division of Transplantation

[2]Baskent University, Department of Radiology

[3]Baskent University, Department of Gastroenterology

Introduction:

- Despite all the developments in the field of surgery, the incidence of biliary complications after liver transplantation is 15-65% and with associated mortality of 10%

- Biliary leaks are the most common biliary complications especially in early postoperative period.

- Various suture techniques, internal and external stents have been used in the literature to prevent biliary leaks.

- In this study, we evaluated the preventive effect of double J stents (djs) placed in the biliary anastomosis on biliary leakage.

Material and Methods:

- Since 1988, we performed 676 liver transplant and 37 of these were between November 2022 and January 2024.
- We used 3Fr X 12cm DJS in the biliary anastomosis of 12 patients.
- Biliary anastomosis was performed using a 2.5 magnifying surgical loupe,
  - end bile duct to side Roux-en-Y hepaticojejunostomy (n = 2),
  - hepaticoduodenostomy (n=2),
  - duct-to-duct choledochocholedochostomy (n=8).
- We performed interrupted suture with 6-0 absorbable material.
- After complete posterior row, we inserted djs into the intrahepatic bile duct.
- After that we complete the anastomosis with interrupted sutures of the anterior wall.
- In biliary anastomoses with multiple ducts, djs were placed separately in each duct.

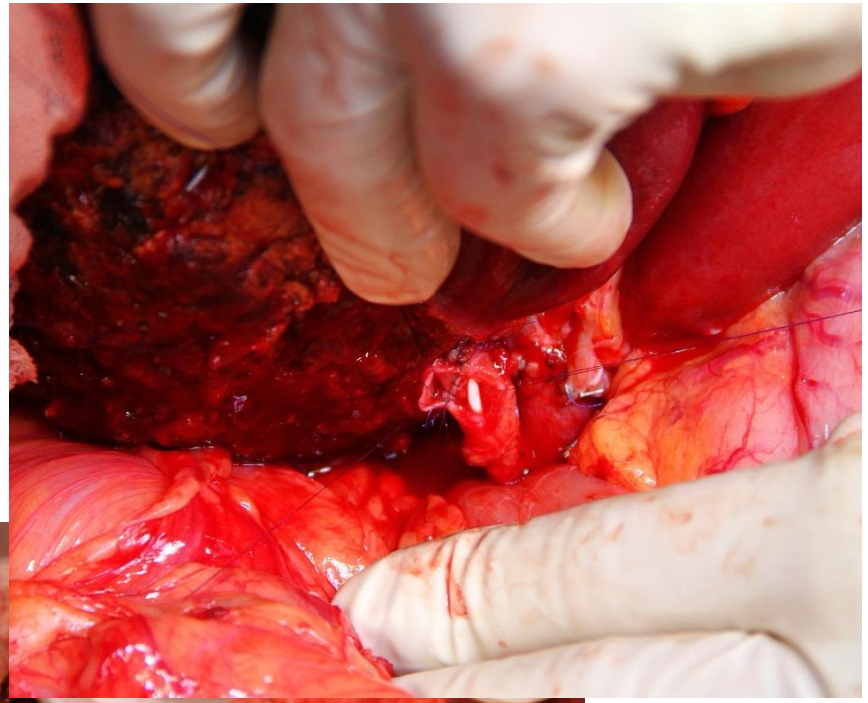

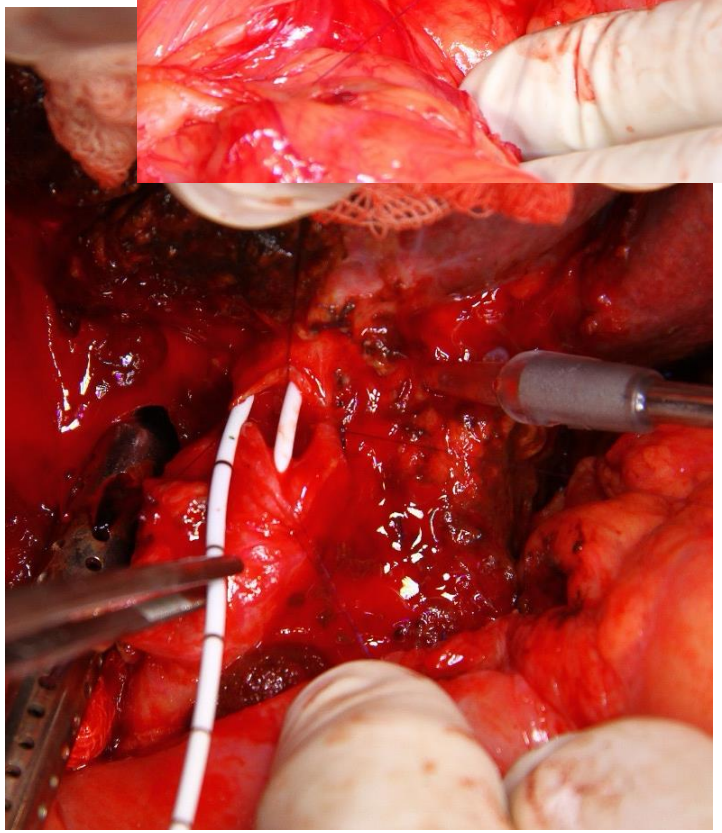

Results:

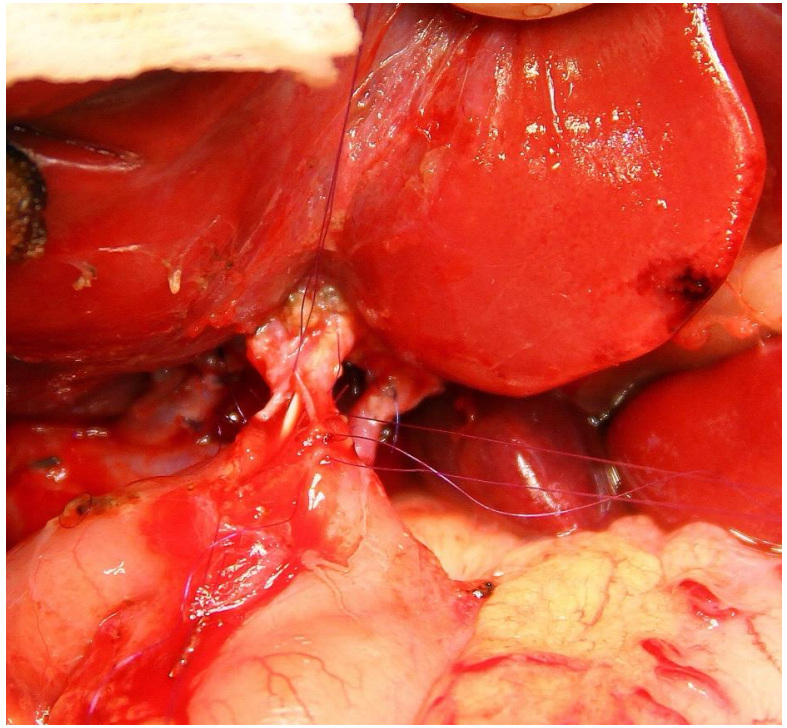

- We used 14 DJS in the biliary anastomosis of 12 patients.
- Six of the recipients were pediatric and six were adults.
- All of the patients were living donor liver transplantation and ABO compatible.
- Of the surgical procedures,
  - 3 were auxiliary partial orthotopic liver transplants
  - 1 was domino liver transplant.
- Of the transplanted grafts,
  - 5 were left lateral lobe,
  - 4 were left lobe,
  - 2 were right lobe
  - 1 was whole graft.
- Eight of the biliary anastomoses were duct-to-duct (DTD) anastomosis, 2 were hepaticojejunostomy (HJS) and 2 were hepaticoduodenostomy.
- Two of the grafts had two bile ducts. In a graft with two bile ducts, we anastomosed the second duct with the cystic duct.
- In the other graft, we anastomosed the two bile ducts to the common bile duct as a single orifice.
- Bile leakage from the anastomosis was observed only in 2 patients.
- In first patient with anastomotic leakage, DJS was endoscopically removed and an internal stent was placed.
- The other patients anastomosis was hepaticoduodenostomy and DJS moved to jejenum.
- We operated for biliary leakage, reinserted DJS and performed primary repair of the anastomotic line.
- Complete recovery was achieved in both of patients without the need for additional intervention and without the development of stenosis.

Conclusion:

- In biliary anastomoses, DJS can be safely used to prevent anastomotic leaks in both pediatric and adult patients, regardless of graft type and anastomosis technique.